RETINOBLASTOMA

BY: DR. KIMANI

DATE: 3RD/APRIL/2017

Introduction

- *Primitive embryonic tumor from undifferentiated retinal elements.*
- *Commonest primary intra ocular malignancy in children.*
- *Frequency 1:14,000 – 1:20,000 live births*
  - *(Kenya – 1:17,000)*
- *30 – 40% → bilateral*
- *94% sporadic, 6% familial.*

GENETICS

- *Autosomal dominant gene on short arm of chromosome 13 at the Q 1,4 segment → recessive behavior*
- *Germinal mutation → transmissible*
- *Somatic → not transmissible*
- *Gene has <u>incomplete penetrance</u>*

Mean age at diagnosis

- *Unilateral: 24 months (Kenya, 35 months)*
- *Bilateral: 12 months (Kenya; 26 months)*
- *90% of cases diagnosed in under 3 years old*
- *Rare in older children and adults*

COMMON SIGNS & SYMPTOMS

- *Leukocoria:*
  - *White pupil (initial s & s in 60 – 70%)*
- *Strabismus (squint):*
  - *Visual axis of the 2 eyes are not aligned (esotropia vs. exotropia)*
- *Red eye*
- *Proptosis:*
  - *The tumor may grow out of the sclera and start growing in the orbit → pushes out the eye*

OTHERS

- *Orbital cellulitis*
  - *The child may present with swollen, painful eyes and lids*
- *Secondary glaucoma*
  - *In growing children, icreased IOP results in 'ox eye/ buphthalmos'*
- *Hyphaema*
  - *Bleeding in the anterior chamber*
- *Nystagmus*
  - *Continuous oscillatory movements of the eye where the eye is not steady; secondary to reduced vision and lack of stimulus to keep the eye steady*
  - *Common in bilateral retinoblastoma*
- *Poor vision*
  - *Common in bilateral retinoblastoma*

Normal pupil would be **3 – 4 mm wide.**
This left pupil is dilated with visible leukocoria.

Fundoscopy findings

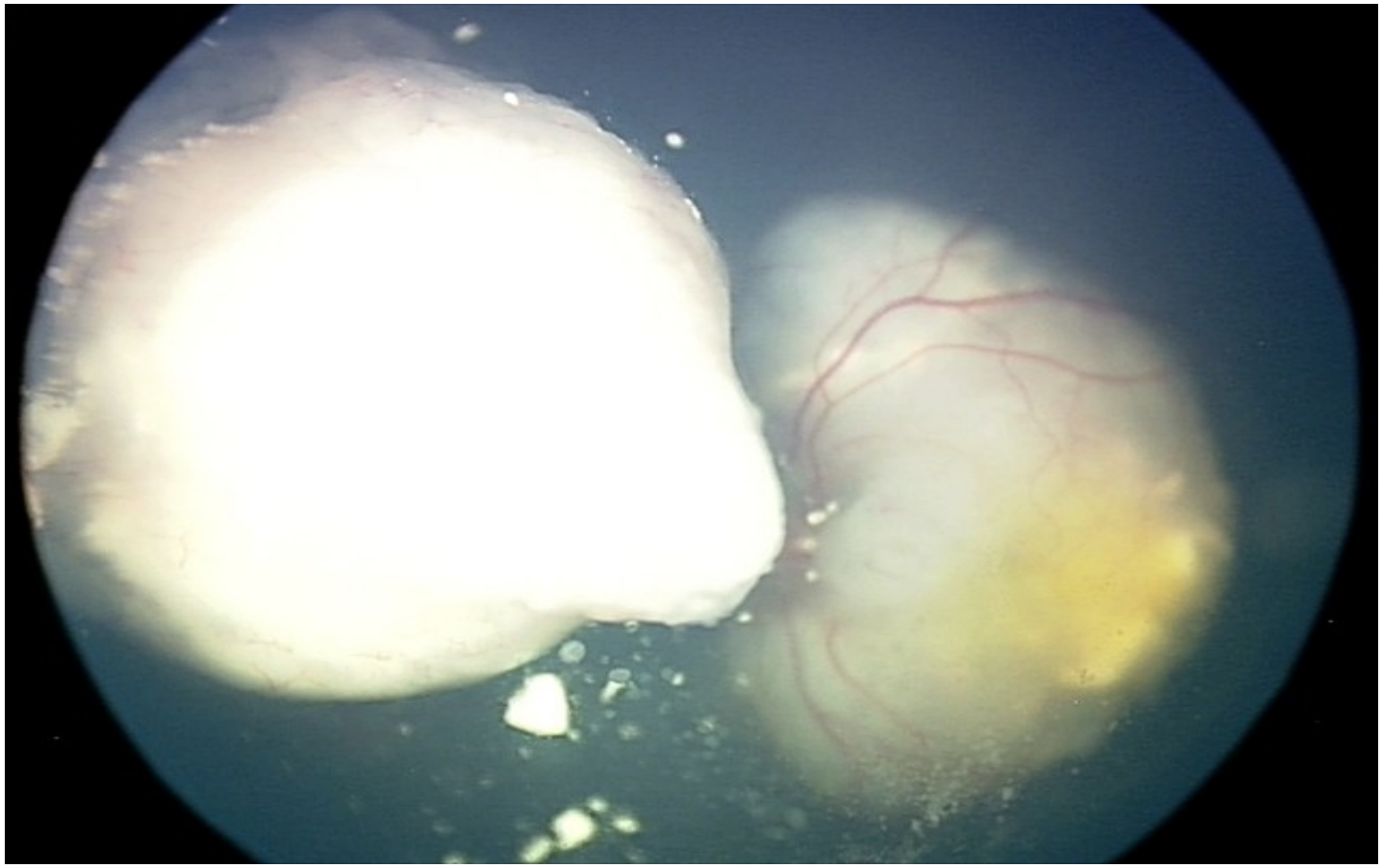

Leukocoria
(MAY BE YELLOWISH IN LONG – STANDING CASES)

Hyphaema

Secondary Glaucoma

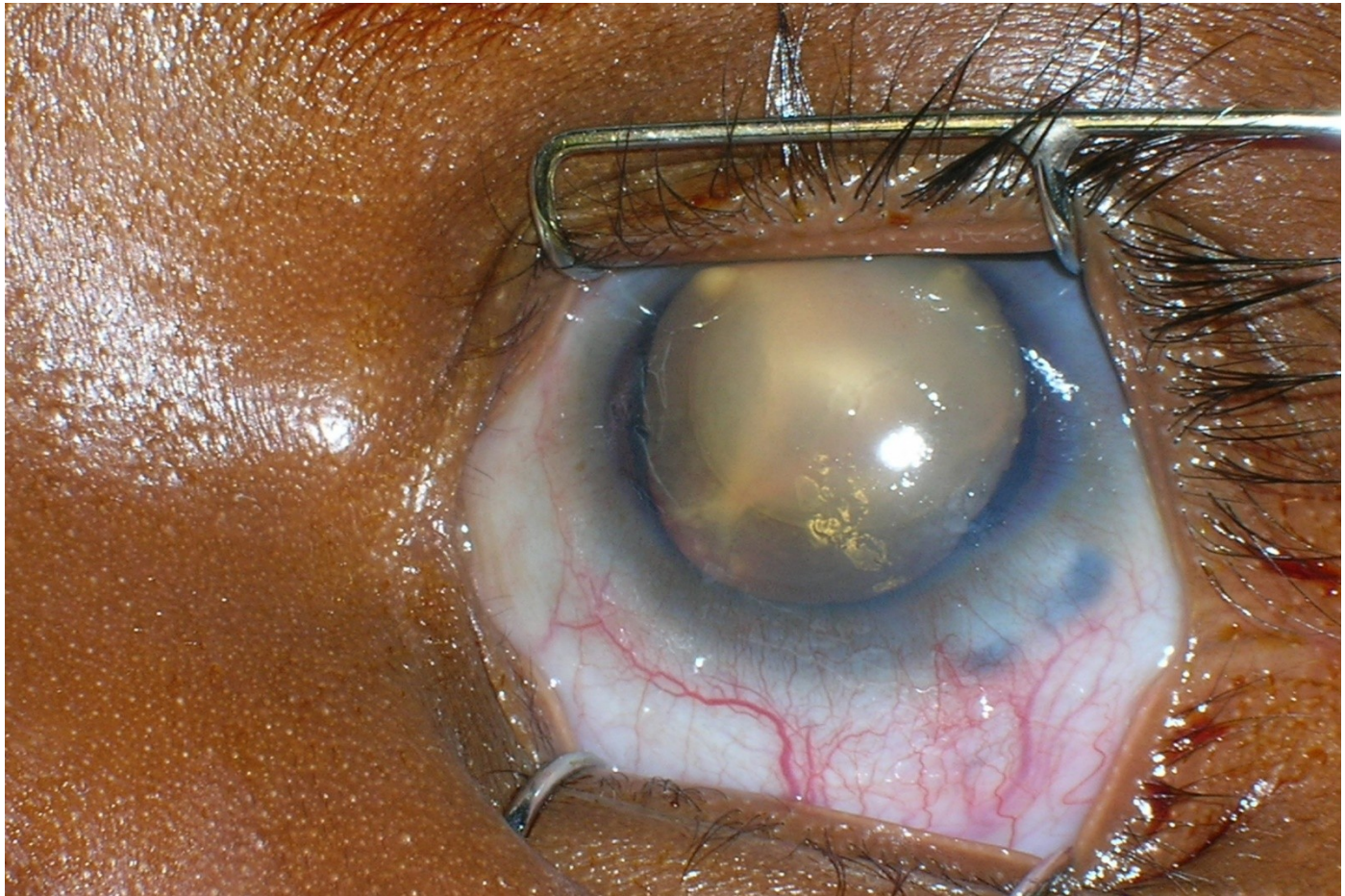

Orbital cellulitis

Proptosis

Familial retinoblastoma

Differential diagnosis for leukocoria (WHITE REFLEX/ PUPIL)

- *Congenital cataract*
- *Retinopathy of prematurity (ROP)*
  - *Preterm birth → retinal vessels are not fully formed → oxygen therapy results in damage and scarring/ fibrosis of the retina*
- *Persistent hyperplastic primary vitreous (PHPV)*
  - *Developmental anomaly whereby when the vitreous is developing, the vascular nature of the vitreous does not regress but persists as a fibrotic band. This is seen as a leucokoria.*
  - *The globe tends to be smaller than usual.*

CONT.

- *Organizing vitreous hemorrhage*
  - *The fibrin clot may appear as a leucokoria*
- *Toxocariasis*
  - *This is a zoonotic disease. Wherever the larvae settle → granulomatous inflammation*
- *Coat's disease*
  - *Abnormal condition → telengiectatic retinal vessels that tend to leak and form exudates in the retina that may appear as a white reflex*
  - *Common diagnosis when one enucleates an eye only to find the diagnosis was not Retinoblastoma histologically*
- *Endophthalmitis*
  - *Pus in the eye secondary to infection*
- *Coloboma of optic nerve or choroid*
  - *Congenital abnormality*

Investigations

- *Retinoblastoma is a clinical diagnosis. The patient may undergo surgery of enucleation of the eye even without supporting investigations.*
- *However, the following investigations help in management:*
  - *Ocular ultrasound*
    - *Calcifications in the tumor give high reflectivity spikes in U/S*
  - *CT scan & MRI*
    - *Mainly for ruling out intracranial metastasis*
    - *One of the commonest routes of spread is through the optic nerve into the brain*
    - *Children with germ line mutation are predisposed to other tumors developing; MRI is therefore preferred to CT scan since one should avoid radiation at all costs in such children.*

CONT.

- *CSF cytology*
  - *In suspected intracranial metastases*
- *Bone marrow aspirate*
  - *In suspected hematogenous spread*
- *Histology (definitive diagnosis)*
  - *Done on enucleated eye*
  - *Also determines whether the tumor is contained within the globe or has spread outside the eye. If the latter is the case, follow enucleation with treatment.*
  - *Small blue cells, necrosis, calcification, Flexner-Wintersteiner rosettes, fleurettes*

CT scan: BILATERAL DISEASE
Hyper dense vitreous

Treatment

- *Enucleation: mainstay of treatment.*
  - *Enucleation in an eye in which the tumor had not spread extra – globularly is curative.*
- *Laser photocoagulation*
- *Cryotherapy*
- *External beam radiation*
  - *NOTE: remember to avoid radiation is paramount*
  - *This should be a last resort.*
- *Brachy therapy*
- *Chemo - reduction: can be delivered systemically or intra – arterial (into the ophthalmic artery)*
- *Systemic chemotherapy/radiotherapy*
- *Gene therapy (research is being done)*

spread

- *Optic nerve: intracranial*
- *Orbit through the sclera and veins*
  - *Presentation: proptosis*
- *Haematogenous:*
  - *Scalp (nodules on scalp), skull, long bones, abdominal viscera (lungs very rare; liver very common)*
- *Lymphatic – Lymph nodes*

Prognosis

- *Confined within eye ball → >95% survival with enucleation. The child should be managed very early.*

Risk factors for death:

- *Delayed management*
- *Extra ocular extension*

- *NB: In bilateral retinoblastoma (germ – line mutations) survivors → increased incidence of non ocular malignancies later in life. This risk is increased by exposure to radiation.*

Tone au alama nyeupe kwenye jicho la mtoto ni dalili ya Saratani (Cancer) ya macho.

Peleka mtoto kwa daktari wa macho haraka

Daisy's Eye Cancer Fund
A Global Response To Childhood Retinoblastoma

Ministry of Health
Division of Opthalmic services
Box 43319 Nairobi
Tel0202729876
Email:dops@health.go.ke

Rattansi Education Trust Building,University way
P.O.Box 63302-00619, Nairobi
Tel: 0720 729 936
Email: eafrica@daisyseyecancerfund.org
Website: www.daisyseyecancerfund.org